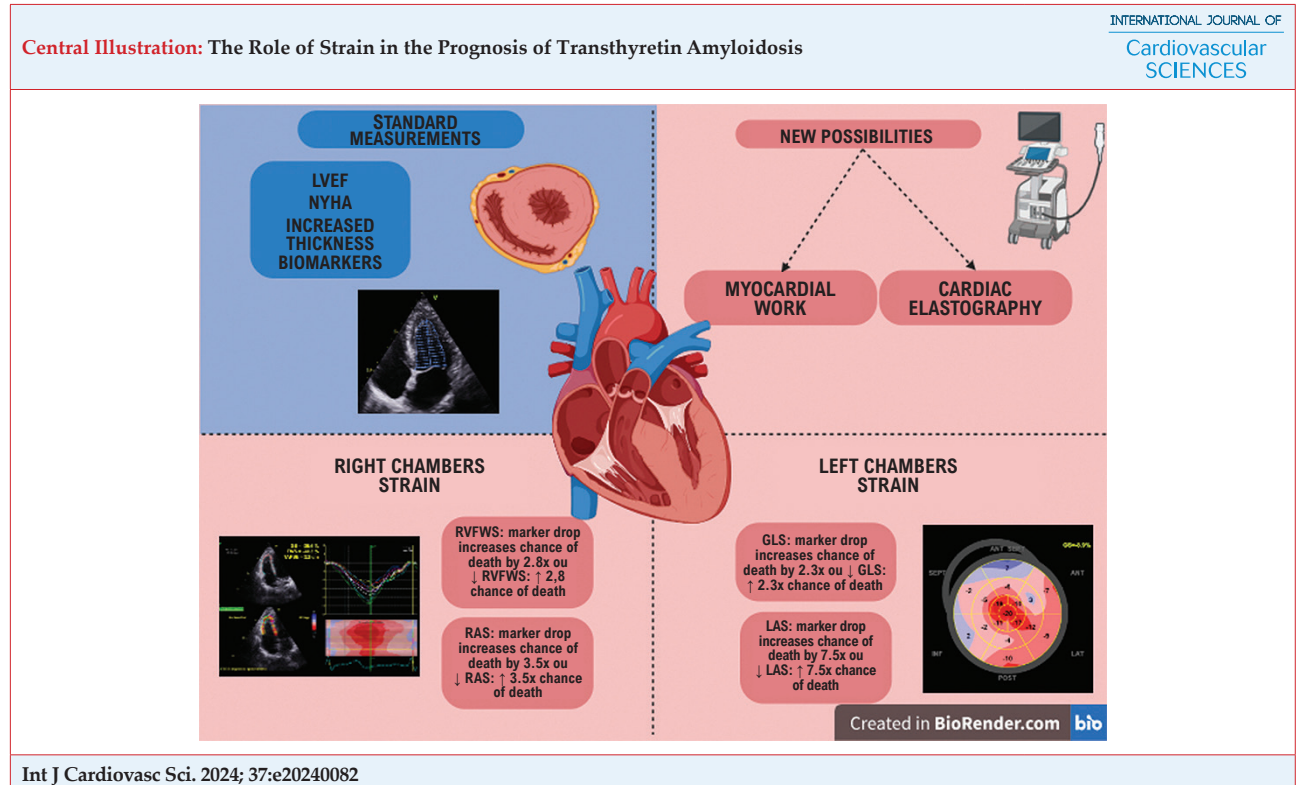


## REVIEW ARTICLE

## The Role of Strain in the Prognosis of Transthyretin Amyloidosis

Ana Karolina Bento Bento da Silva,<sup>1</sup> Leonardo Torreão Bezerra Cavalcanti,<sup>1</sup> Silvio Henrique Barberato,<sup>2</sup> Alex dos Santos Felix,<sup>3</sup> Marcelo Dantas Tavares de Melo<sup>1</sup>

Universidade Federal da Paraíba,<sup>1</sup> João Pessoa, PB – Brazil  
 Cardioeco, Centro de Diagnóstico Cardiovascular,<sup>2</sup> Curitiba, PA – Brazil  
 Instituto Nacional de Cardiologia,<sup>3</sup> Rio de Janeiro, RJ – Brazil



LVEF: Left ventricular ejection fraction; RVFWS: Right ventricular free wall strain; RAS: Right atrium strain; GLS: global longitudinal strain; LAS: Left atrium strain; NYHA: New York Heart Association Classification of Heart Failure.

### Abstract

Transthyretin amyloidosis (TTRA) is a systemic infiltrative disease where cardiac involvement is paramount for prognosis. The strain technique plays a crucial role in non-invasive cardiac screening for

this condition. Research on the prognostic utility of cardiac deformation in TTRA indicates the significance of right ventricular (RV) free wall strain, global longitudinal strain (GLS), left and right atrium reservoir strain, in descending order of publication, respectively. The GLS has emerged as a promising tool for therapeutic monitoring. Analyzing myocardial deformation is vital due to its incremental value over other clinical, laboratory, and imaging parameters. However, caution is warranted due to limited data

### Keywords

Echocardiography; Cardiomyopathies; Heart Failure.

#### Mailing Address: Ana Karolina Bento Bento da Silva

Universidade Federal da Paraíba, Campus I. Loteamento, cidade universitária. Postal code: 58051-900. João Pessoa, PB – Brazil  
 E-mail: Anakarolinabentos@gmail.com  
 Editor responsible for the review: Marcus Vinícius Simões

on its prognostic and therapeutic monitoring use in TTRA. Despite the strong rationale for employing myocardial deformation in patient stratification, further robust studies are necessary to establish it as a new prognostic marker in TTRA.

## Introduction

TTRA results from the misfolding and deposition of transthyretin monomers, a tetrameric protein synthesized by the liver that normally functions to transport thyroid hormone and retinol. Among its clinical manifestations, cardiomyopathy is considered the main factor of poor prognosis, affecting approximately 50,000 to 150,000 people in the USA. In Brazil, it is estimated that there are more than 5,000 patients who have TTRA with cardiac involvement.<sup>1-3</sup>

Transthyretin amyloidosis (TTRA) is categorized in two main forms: one resulting from mutations in the transthyretin gene (TTRAv), inherited in an autosomal dominant manner, with its gene located on chromosome 18 and over 140 mutations described to date. The other form, known as wild-type TTRA (wtTTRA), involves a normal amino acid sequence, although the mechanism by which the wild-type protein becomes unstable remains not completely understood.<sup>2</sup> This type is believed to be the most common form of TTRA amyloidosis, accounting for approximately 75% of cases and typically presenting as cardiomyopathy, with less than 10% of patients concurrently experiencing polyneuropathy.<sup>1</sup>

TTRA manifests mainly as cardiomyopathy and/or polyneuropathy, depending on the mutation and interaction of amyloid fibrils in the body. Myocardial deposition leads to progressive loss of myocardial compliance, clinically presenting as heart failure with preserved ejection fraction (HFpEF), arrhythmias, dysautonomia, and ultimately, death. In advanced stages, myocardial deposits cause severe diastolic dysfunction and a reduction in ejection fraction.<sup>1</sup>

Studies indicate that wild-type transthyretin amyloidosis (wtTTRA) is relatively common among older adults with HFpEF and severe aortic stenosis, particularly in those with low flow and low gradient.<sup>4</sup>

The suspicion of amyloidosis arises in patients with unexplained left ventricular (LV) hypertrophy, regardless of age, accompanied by various symptoms such as syncope, pre-syncope, dyspnea, angina, and signs of systemic involvement. Transthoracic echocardiography serves as the primary diagnostic tool

for assessing structural changes in patients suspected of cardiac amyloidosis (CA). However, imaging faces challenges in differentiating cardiomyopathies based on phenocopies, particularly distinguishing between hypertrophic and dilated forms. With the improvement of imaging techniques, together with the genetic study being more accessible in clinical practice, it is now clear that the morphology is insufficient for a precise diagnosis. The study of cardiac mechanics, particularly in phenocopies with increased thickness, allows us to find unique patterns for each one, for which the term "fingerprint" is used.<sup>1,4</sup>

In 2012, Phelan et al. revealed that a pattern of relative apical preservation measured by Global Longitudinal Strain (GLS), compared with arterial hypertension, hypertrophic cardiomyopathy, and aortic stenosis, was both specific and sensitive for the diagnosis of CA. This characteristic is not exclusive to the LV, as the involvement of the right ventricle (RV) also presents affected mid-basal regions.<sup>5</sup>

The evolution of multimodality imaging in amyloidosis plays a central role in the diagnosis of CA, evidencing the parametric presentation of strain, which gained popularity as a synonym for amyloidosis (apical sparing, cherry on top, for example). Nevertheless, there remains a significant gap in the use of myocardial deformation analysis among these patients and its implications for prognostic stratification. In this review, the main articles on the matter will be analyzed with a critical view.

## Discussion

TTRA is generally a progressive disease with a poor prognosis when not diagnosed and treated in its early stages. Echocardiography provides information that helps predict cardiovascular outcomes in patients with TTRA. Given that LV ejection fraction often remains normal until the disease reaches advanced stages, reliance on other echocardiographic indices becomes crucial for symptom interpretation and risk stratification. Several echocardiographic indices were independently associated with higher mortality rates in TTRA, such as indexed stroke volume, indexed right atrium area, E/e' ratio and GLS.<sup>6</sup> In fact, subclinical dysfunction of all cardiac chambers appears to have additional prognostic significance, as strain-derived data showed an association with higher mortality.<sup>7</sup>

The position on Diagnosis and Treatment of Cardiac Amyloidosis by the Brazilian Society of Cardiology

establishes that the prognosis of this disease is measured through the emergence and duration of HF symptoms. As a result, low-cost laboratory tests have been used in different proposals for staging the disease, thereby obtaining a good level of correlation with life expectancy (serum levels of troponin T and I, glomerular filtration rate, NT-proBNP). Furthermore, the evident contribution of imaging exams to the prognostic assessment of patients with TTRA converges into the same group: Echocardiogram, Cardiac Magnetic Resonance Imaging, and Myocardial Scintigraphy with Tc99. Regarding echocardiography, the document reveals the following metrics related to prognosis: LVEF, myocardial contraction fraction, GLS, and apical preservation.<sup>8</sup>

There is a consensus regarding the use of functional class, biomarkers, reduced ejection fraction, and diastolic dysfunction for prognostic stratification in these patients.<sup>9,10</sup> Table 1 summarizes the primary prognostic scores in TTRA, emphasizing the use of biomarkers.

The 2023 American College of Cardiology expert consensus underscores the pivotal role of echocardiography in diagnosing TTRA, particularly in elucidating the prognostic significance of myocardial deformation.<sup>10</sup> Given the challenges and limitations associated with clinical, laboratory, and imaging modalities, the study of cardiac chamber deformation enhances the robustness of clinical and therapeutic monitoring. Despite the growing interest in this technique, it lacks consensus regarding its use for prognosis assessment in the literature, while also not being addressed in the prognosis and follow-up guidelines of recent society publications as other strain tools for different cardiac chambers. Table 2 provides a summary of the main articles collected on the analysis of TTRA deformation and prognosis.

### RV Strain

The analysis by Peter R. Huntjens et al. corroborates the 2021 SBC position, showing that decreased GLS values were associated with a poor prognosis. The research also highlighted the significant role of right ventricular free wall strain (RVFWS) in prognostic stratification, with a decrease in this index (<17%) correlating with a 2.8-fold increase in the likelihood of cardiovascular death.<sup>7</sup> Similarly, Nowell M. Fine et al. observed during annual follow-up that the decline in RVFWS was more pronounced in the group experiencing cardiovascular death (reduction >2%), notably lower in the TTRA group compared to patients with light

**Table 1 – TTRA staging according to biomarkers.**

Studies	Biomarkers cut-off value	Staging	Prognosis (in months)
Grogan et al., 2016 <sup>11</sup>	wtTTRA: NT-proBNP > 3000 ng/l cTnT > 0.05 mcg/l	Stage I: NT-proBNP < 3000 ng/l and/or cTnT < 0.05 mcg/l Stage II: NT-proBNP OR cTnT above the cut-off value Stage III: NT-proBNP and cTnT above the cut-off value	Stage I: 66 Stage II: 40 Stage III: 20
Hanson et al., 2018 <sup>12</sup>	wtTTRA: sTTR < 18 mg/dL Tncl < 0.049 ng/ml	sTTR < 18 mg/dL sTTR > 18 mg/dL	33 49
Gillmore et al., 2018 <sup>13</sup>	wtTTRA, NT-proBNP > 3000 ng/l hTTRA, eGFR < 45 ml/min	Stage I: NT-proBNP < 3000 ng/l and/or eGFR > 45ml/min Stage II: NT-proBNP OR eGFR > 45ml/min Stage III: NT-proBNP and eGFR > 45ml/min	Stage I: 69,2 Stage II: 46,7 Stage III: 24,1

*wtTTRA: Wild-type transthyretin amyloidosis; hTTRA: Hereditary transthyretin amyloidosis; Nt-proBNP: N-terminal pro-B-type natriuretic peptide; cTnT: Cardiac troponin T; cTnI: Cardiac troponin I; eGFR: estimated glomerular filtration rate; LVEF: Left ventricular ejection fraction; sTTR: Serum transthyretin dosage.*

chain amyloidosis (LA), thus rendering this measure more sensitive for quantifying ventricular mechanical function.<sup>17</sup> Supporting this observation, Hiroki Usuku et al. identified free wall strain as an independent variable associated with cardiovascular death, demonstrating a sensitivity of 69.2% and specificity of 63.5%.<sup>20</sup> Moreover, the RVFWS indicator (< 11.59%) alone was directly correlated with cardiovascular death and the number of hospitalizations for heart failure.<sup>17,20</sup> Notably, conventional echocardiographic findings commonly linked to RV function, such as tricuspid annular plane systolic excursion (TAPSE) and fractional change in RV area (FAC-RV), did not achieve statistical significance according to the study by Hiroki Usuku et al.<sup>20</sup> The suggested explanation for this observation stems from the potential impact of the apical movement of the LV on TAPSE, which could lead to over or underestimation

Table 2 – Summary of evidence.

Author, date	Objectives	Sample	Echocardiographic Parameters	Findings	Results
Bodez et al., 2016 <sup>14</sup>	To investigate the prognostic value of RV dysfunction in patients with CA.	n = 82	TAPSE RVFWS	TAPSE < 14mm	TAPSE was found to be a prognostic marker, reflecting RV and LV involvement.
Solomon et al., 2019 <sup>15</sup>	Effects of Patisiran on cardiac structure and function in patients with CA.	n = 126	LV thickness GLS LVEF	GLS reduction > 2%	Treatment with Patisiran resulted in reduced LV wall thickness and improved GLS compared to placebo.
Minamisawa et al, 2019 <sup>16</sup>	To evaluate the association of Patisiran treatment with a regional strain of the LV myocardium in the cardiac manifestation of TTRA amyloidosis.	n = 126	LVGLS	LVGLS improvement = 1.4% compared to placebo	Patisiran prevented the deterioration of LV GLS over 18 months, mainly by attenuating disease progression in the basal region.
Fine et al., 2020 <sup>17</sup>	Prognostic relevance of right and left chamber function in CA.	n = 97	TAPSE LVEF GLS RVFWS	RVFWS reduction > 1.2% GLS reduction > 1.4%	RVFWS was associated with mortality and the need for cardiovascular hospitalization. GLS changes were associated with adverse outcomes.
Huntjens et al., 2021 <sup>7</sup>	Prognostic value of atrial and ventricular deformation in patients with CA.	n = 136	LVEF TAPSE GLS RVFWS LAS RAS LV thickness	RVFWS < 17.0% GLS < 10.4% LAS < 13.2% RAS < 12.4%	Decreased RVFWS, GLS, LAS, and RAS indexes showed a correlation with the chance of death: 2.8x, 2.3x, 7.5x and 3.5x greater the chance, respectively.
Tjahjadi et al., 2022 <sup>18</sup>	To investigate the prognosis associated with right chamber dysfunction in patients with CA.	n = 93	RVFWS TAPSE	RVFWS < 16%	The use of RVFWS was associated with an incremental prognostic value compared to conventional echocardiographic parameters such as TAPSE.
Giblin et al., 2022 <sup>19</sup>	Natural history of myocardial function in untreated CA, and determination of the effect of Tafamidis on myocardial functional parameters in a 12-month treatment program.	n = 45	GLS Myocardial work index Myocardial efficiency	GLS: -0.3% vs -1.1%*	Tafamidis in TTRA-CM decreases the deterioration of cardiac function, as measured by GLS and myocardial work index over 1 year, when compared with an untreated cohort.
Usuku et al., 2022 <sup>20</sup>	To investigate whether GLS provides prognostic information in patients with CA.	n = 129	RVFWS GLS	RVFWS < 11.59%	GLS has prognostic value in patients with TTRA and provides greater prognostic power compared to conventional echocardiographic findings.

Shah et al., 2024 <sup>21</sup>	To analyze the effect of Tafamidis on cardiac function in patients with TTRA	n = 436	LVGLS	LVGLS decline = 1.84% compared to placebo	A mild decline was seen in LVSG with Tafamidis, 80 mg, vs. placebo in the mid and basal regions, while an attenuated decline in LV circumferential and radial strain was observed in the mid and apical regions.
---------------------------------	--	---------	-------	---	--

TAPSE: tricuspid annular plane systolic excursion; RV: Right ventricle; LV: Left ventricle; GLS: Global longitudinal strain; LVEF: Left ventricular ejection fraction; LVGLS: Left ventricular global longitudinal strain; RVFWS: Right ventricular free wall strain; LAS: Left atrium strain; RAS: Right atrium strain; TTRA: Transthyretin amyloidosis; CA: cardiac amyloidosis.

of RV function based on transducer angulation.<sup>10</sup> Conversely, Bodez et al. found TAPSE to be a significant independent predictor of major cardiac events within 6 months, unlike other parameters assessing RV systolic function. As a result, the study recommends incorporating this measurement into the routine evaluation of patients with CA, with a suggested TAPSE cut-off point of < 14 mm.<sup>14</sup>

Catherine Tjahjadi et al., while identifying TAPSE as an independently related parameter to cardiovascular death, demonstrated that RVFWS (<16%) exhibited a stronger association with all-cause mortality, offering incremental prognostic value over conventional parameters of RV systolic function.<sup>18</sup> Therefore, two parameters of RV longitudinal systolic function emerge, with RVFWS serving as a more sensitive marker for subclinical detection and TAPSE as a more specific parameter characterized by less interobserver variability and better reproducibility. Therefore, patients may present with incipient RV involvement and normal TAPSE, although they more frequently present a reduction in RVFWS, which may be a justification for the result described. In

this study, patients with reduced TAPSE apparently had more advanced disease.

### LV Strain

On echocardiography, patients with TTRA cardiomyopathy typically show increased LV wall thickness, preserved ejection fraction, different degrees of diastolic dysfunction and reduced SGL.<sup>1</sup> The prognostic importance of the initial measurement GLS has been consolidated in patients with both cardiac amyloid subtypes, regardless of other imaging, laboratory and clinical variables.<sup>17</sup> Barros-Gomes et al. showed that SGL provided incremental prognostic value in 61 patients with LA CA over the current validated LA staging system in patients with preserved LVEF. Thus, it was related to a worse GLS prognosis of less than 14.81%.<sup>22</sup>

The findings of Nowell M. Fine et al. corroborate other studies describing the prognostic value of GLS and demonstrating that the progressive decline of GLS during follow-up is associated with a poor prognosis (reduction > 1.4%).<sup>17</sup> (Figure 1). In the study by Peter R. Huntjens et

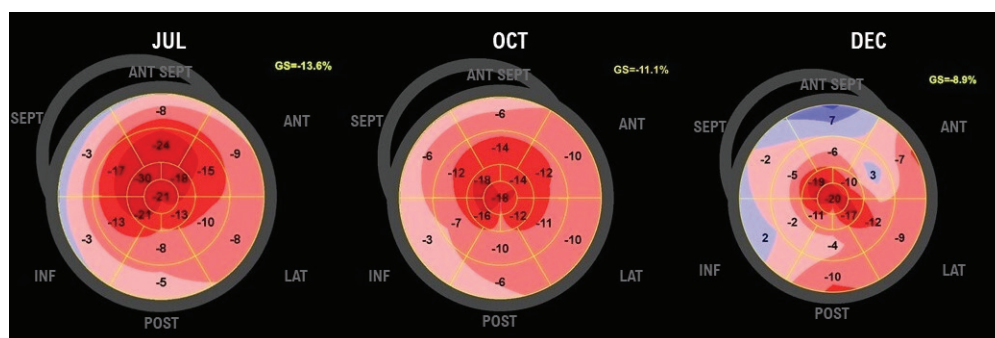


Figure 1 – Temporal evolution of GLS in a patient with CA, demonstrating disease progression and eventual death within 6 months. A gradual and progressive decline in GLS is evident, with a distinct presentation in the parametric analysis, notably sparing the apex.

al., reducing this metric was associated with a 2.3-fold increase in the risk of death. In this study, the cutoff point was classified as GLS < 10.4%.<sup>7</sup> However, the frequency, modality and ideal parameters for evaluating follow-up cardiac images of patients with CA remain uncertain.<sup>17,20</sup>

### Left Atrium Strain

The left atrium is an extremely thin chamber, which makes it a challenge for tissue analysis using imaging methods. Its involvement in amyloidosis would be intuitively attributed to LV diastolic dysfunction. However, investigations conducted on explanted hearts have revealed the presence of amyloid infiltrate, fibrosis, and disorganization of atrial fibers. Consequently, it is understood that left atrial involvement can manifest even in the absence of significantly elevated filling pressures in the LV. The analysis of left atrial deformation in amyloidosis indicates a reduction across its three phases (reservoir, conduit, and contraction).<sup>23</sup> Notably, when assessing strain via the four-chamber view, a decrease in strain of the RV, right atrium, LV, and left atrium has been linked to poor prognosis. Interestingly, left atrial reservoir strain emerged as the most significant parameter for prognostic stratification, with a cutoff point below 13.2%.<sup>7</sup>

A prospective study from 2018 by the University Hospital of Limoges, France, using three-dimensional echocardiography, concluded that the three-dimensional strain of the left atrial reservoir (LAS) has a good correlation with the Mayo Clinic clinical stages in patients with LA amyloidosis.<sup>24</sup> Under this perspective, the study by Peter R. Huntjens brings the study of LAS as a prognostic measure in patients with TTRA. It demonstrates that LAS is additive to GLS and independently associated with survival in patients with CA. In this study, a cutoff point of LAS < 13.2% was adopted, with a decrease in this parameter corresponding to a 7.5-fold increase in the risk of death. Thus, LAS reflects more advanced cardiac involvement in CA and, therefore, shows potential as a new prognostic marker.<sup>7</sup>

### Right Atrium Strain

Assessment of the right atrium is limited due to geometric difficulties in two-dimensional echocardiography. However, three-dimensional echocardiography is a new clinical modality that allows accurate measurement of atrial volume changes. The MAGYAR-Path study demonstrates right atrial

strain (RAS) as an alternative for the evaluation of patients with AL, showing a correlation between this measurement and cardiac dysfunction.<sup>25</sup> However, the study does not define this index as having diagnostic or prognostic value.

A study by Peter R. Huntjens et al. uses RAS as a new parameter for prognostic assessment in patients with TTRA. In this sense, RAS lower than the median of 12.4% was associated with a 3.5-fold increase in the risk of death.<sup>7</sup>

### New Tools

#### Myocardial Work

Non-invasive assessment of myocardial work using echocardiographic software is a relatively novel approach, showing promise in the context of TTRA. However, it remains an area requiring further exploration. In the context of aortic stenosis, both with and without amyloidosis, a limited number of studies have highlighted the myocardial work index as a superior prognostic indicator for mortality compared to LV ejection fraction and GLS.<sup>26</sup> In a single-center study involving 113 patients with wtTTRA, the myocardial work index demonstrated added prognostic value in predicting outcomes such as death and hospitalization for heart failure within this population.<sup>27</sup>

#### Cardiac Elastography

The use of the elastography technique for assessing cardiac stiffness has been previously explored through cardiac magnetic resonance imaging.<sup>28</sup> While elastography is commonly employed using ultrasound to evaluate liver stiffness in patients with cirrhosis, thus reducing the necessity for routine biopsies,<sup>29</sup> there is a growing interest in applying this technique directly to assess cardiac stiffness. In CA, cardiac elastography has demonstrated not only a strong correlation between cardiac stiffness and various clinical, laboratory, and imaging parameters but also provides incremental prognostic value for these patients.<sup>30</sup> This tool is expected to attract increasing attention for studies focusing on phenocopies characterized by increased thickness and reduced compliance.

#### Value of Testing for the Impact of Existing Therapies

Conventional echocardiographic, clinical and biomarker indicators have been established to evaluate treatment in

LA. However, the use of similar markers in the treatment of TTRA has been limited due to their variability.

The TTRA-ACT study primarily aimed to evaluate the efficacy, safety and tolerability of Tafamidis compared to placebo for the treatment of TTRA. Assessment of intervention efficacy was conducted based on the 6-minute walk test, changes in the Kansas City Cardiomyopathy Questionnaire-Overall Summary (KCCQ-OS) score, and the NYHA classification.<sup>24</sup> In a study by Ahmed Ghoneem et al., the effectiveness of Tafamidis versus placebo was evaluated solely based on heart failure exacerbation events without incorporating objective metrics.<sup>31</sup> Similarly, in a study by Mathew S. Maurer et al., outcomes associated with Patisiran were assessed using the 6-minute walk test, KCCQ-OS score, and composite endpoints, including all-cause mortality and heart failure-related hospitalizations.<sup>32</sup> However, these studies did not delve into more comprehensive analyses, such as incorporating imaging modalities to evaluate therapy effectiveness.

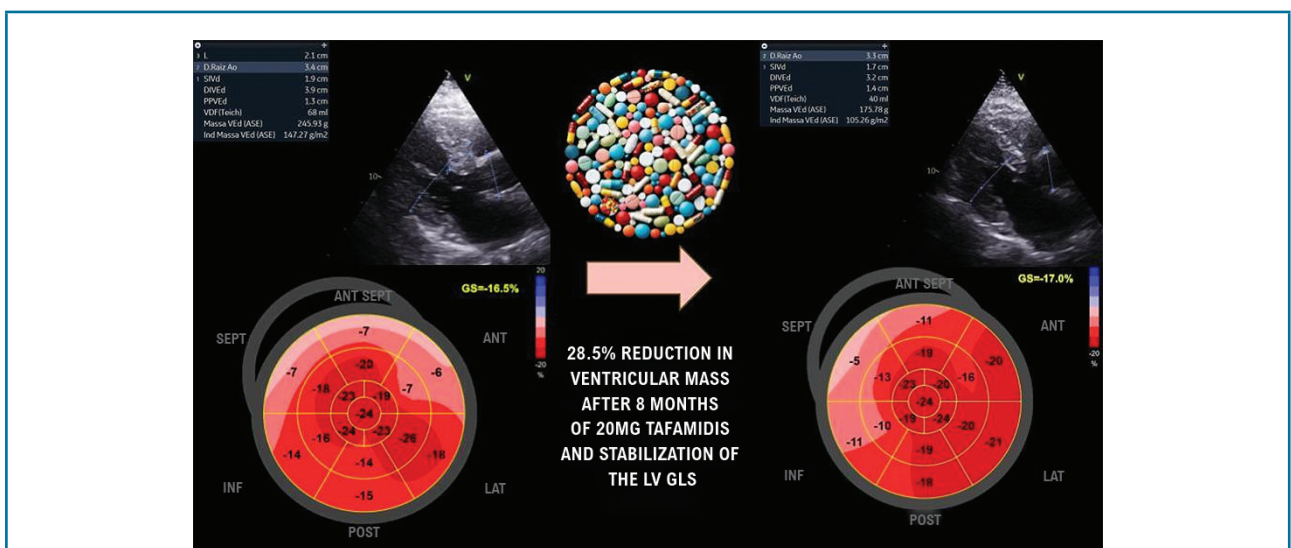
Giblin et al. bring echocardiographic monitoring as an alternative to evaluate the impacts of drug therapy as a reproducible, objective and non-invasive method. In their analysis, they used the GLS to evaluate the impact of treatment with Tafamidis. In absolute terms, GLS deteriorated by a median of 0.3% over one year in treated patients, a rate lower than that found in patients who did not use the medication (1.1%) (Figure 2).<sup>19</sup>

Another study revealed that higher doses of Tafamidis at 80 mg versus placebo resulted in a mild decline LVGLS in the mid and basal regions of the LV (-1.84; 95% CI, -2.79 to -0.89; P<.001), along with a reduced decline in LV circumferential and radial strain in the mid and apical regions.<sup>33</sup> Similar effects were subsequently observed in patients using Patisiran. In this context, a study indicated a reduction in LV wall thickness and a decrease in GLS (>2%) in the Patisiran group compared to placebo.<sup>19</sup> Another study involving the same drug also showcased an enhancement in absolute GLS (1.4% [0.6%]; 95% CI, 0.3%-2.5%; P = 0.02) compared to placebo over an 18-month follow-up period.<sup>21</sup>

While these findings provide promising insights, they should be interpreted with caution due to the limited evidence on the efficacy of echocardiography and strain in assessing therapeutic response. This reinforces the uncertainty surrounding the categorical and systematic use of these tools for this purpose despite their strong plausibility. The central illustration summarizes the key points discussed in this review.

## Conclusion

The integration of myocardial deformation analysis holds significant importance due to its supplementary role alongside clinical, laboratory, and imaging parameters.



**Figure 2 – This illustration exemplifies the impact of a disease-modifying drug (Tafamidis), demonstrating reduced ventricular mass and stabilized cardiac mechanics (global longitudinal strain).**

GLS: Global Longitudinal Strain; SEPT: Septum; ANT: Anterior; INF: Inferior; POST: Posterior

However, cautious interpretation is warranted due to the limited data regarding its application in TTRA, particularly when employed independently. The current scenario offers a promising opportunity for future research to validate the reliability of this parameter in prognostic stratification for this condition.

## Author Contributions

Conception and design of the research, analysis and interpretation of the data and writing of the manuscript: Silva AKBB, Cavalcanti LTB, Melo MDT; acquisition of data: Silva AKBB, Cavalcanti LTB; critical revision of the manuscript for intellectual content: Barberato SH, Felix AS, Melo MDT.

## References

- Ruberg FL, Maurer MS. Cardiac Amyloidosis Due to Transthyretin Protein: A Review. *JAMA*. 2024;331(9):778-91. doi: 10.1001/jama.2024.0442.
- Finsterer J, Iglseder S, Wanschitz J, Topakian R, Löscher WN, Grisold W. Hereditary Transthyretin-related Amyloidosis. *Acta Neurol Scand*. 2019;139(2):92-105. doi: 10.1111/ane.13035.
- Pedrosa RC. Amyloidosis for Cardiologists. *Arq Bras Cardiol*. 2022;118(2):433-4. doi: 10.36660/abc.20210959.
- Fontana M, Ćorović A, Scully P, Moon JC. Myocardial Amyloidosis: The Exemplar Interstitial Disease. *JACC Cardiovasc Imaging*. 2019;12(11):2345-56. doi: 10.1016/j.jcmg.2019.06.023.
- Phelan D, Collier P, Thavendiranathan P, Popović ZB, Hanna M, Plana JC, et al. Relative Apical Sparing of Longitudinal Strain Using Two-dimensional Speckle-tracking Echocardiography is Both Sensitive and Specific for the Diagnosis of Cardiac Amyloidosis. *Heart*. 2012;98(19):1442-8. doi: 10.1136/heartjnl-2012-302353.
- Chacko L, Martone R, Bandera F, Lane T, Martinez-Naharro A, Boldrini M, et al. Echocardiographic Phenotype and Prognosis in Transthyretin Cardiac Amyloidosis. *Eur Heart J*. 2020;41(14):1439-47. doi: 10.1093/eurheartj/ehz905.
- Huntjens PR, Zhang KW, Soyama Y, Karpmpalioti M, Lenihan DJ, Gorscan J 3rd. Prognostic Utility of Echocardiographic Atrial and Ventricular Strain Imaging in Patients With Cardiac Amyloidosis. *JACC Cardiovasc Imaging*. 2021;14(8):1508-19. doi: 10.1016/j.jcmg.2021.01.016.
- Simões MV, Fernandes F, Marcondes-Braga FG, Scheinberg P, Correia EB, Rohde LEP, et al. Position Statement on Diagnosis and Treatment of Cardiac Amyloidosis - 2021. *Arq Bras Cardiol*. 2021;117(3):561-98. doi: 10.36660/abc.20210718.
- Cotella J, Randazzo M, Maurer MS, Helmke S, Scherrer-Crosbie M, Soltani M, et al. Limitations of Apical Sparing Pattern in Cardiac Amyloidosis: A Multicentre Echocardiographic Study. *Eur Heart J Cardiovasc Imaging*. 2024;25(6):754-61. doi: 10.1093/ehjci/jeae021.
- Kittleson MM, Ruberg FL, Ambardekar AV, Brannagan TH, Cheng RK, Clarke JO, et al. 2023 ACC Expert Consensus Decision Pathway on Comprehensive Multidisciplinary Care for the Patient With Cardiac Amyloidosis: A Report of the American College of Cardiology Solution Set Oversight Committee. *J Am Coll Cardiol*. 2023;81(11):1076-126. doi: 10.1016/j.jacc.2022.11.022.
- Grogan M, Scott CG, Kyle RA, Zeldenrust SR, Gertz MA, Lin G, et al. Natural History of Wild-Type Transthyretin Cardiac Amyloidosis and

## Potential Conflict of Interest

No potential conflict of interest relevant to this article was reported.

## Sources of Funding

There were no external funding sources for this study.

## Study Association

This study is not associated with any thesis or dissertation work.

## Ethics Approval and Consent to Participate

This article does not contain any studies with human participants or animals performed by any of the authors.

- Risk Stratification Using a Novel Staging System. *J Am Coll Cardiol*. 2016;68(10):1014-20. doi: 10.1016/j.jacc.2016.06.033.
- Hanson JLS, Arvanitis M, Koch CM, Berk JL, Ruberg FL, Prokavaeva T, et al. Use of Serum Transthyretin as a Prognostic Indicator and Predictor of Outcome in Cardiac Amyloid Disease Associated With Wild-Type Transthyretin. *Circ Heart Fail*. 2018;11(2):e004000. doi: 10.1161/CIRCHEARTFAILURE.117.004000.
- Gillmore JD, Damy T, Fontana M, Hutchinson M, Lachmann HJ, Martinez-Naharro A, et al. A New Staging System for Cardiac Transthyretin Amyloidosis. *Eur Heart J*. 2018;39(30):2799-806. doi: 10.1093/eurheartj/ehx589.
- Bodez D, Ternacle J, Guellich A, Galat A, Lim P, Radu C, et al. Prognostic Value of Right Ventricular Systolic Function in Cardiac Amyloidosis. *Amyloid*. 2016;23(3):158-67. doi: 10.1080/13506129.2016.1194264.
- Solomon SD, Adams D, Kristen A, Grogan M, González-Duarte A, Maurer MS, et al. Effects of Patisiran, an RNA Interference Therapeutic, on Cardiac Parameters in Patients With Hereditary Transthyretin-Mediated Amyloidosis. *Circulation*. 2019 2;139(4):431-43. doi: 10.1161/CIRCULATIONAHA.118.035831.
- Minamisawa M, Claggett B, Adams D, Kristen AV, Merlini G, Slama MS, et al. Association of Patisiran, an RNA Interference Therapeutic, With Regional Left Ventricular Myocardial Strain in Hereditary Transthyretin Amyloidosis: The APOLLO Study. *JAMA Cardiol*. 2019;4(5):466-72. doi: 10.1001/jamacardio.2019.0849.
- Fine NM, White JA, Jimenez-Zepeda V, Howlett JG. Determinants and Prognostic Significance of Serial Right Heart Function Changes in Patients With Cardiac Amyloidosis. *Can J Cardiol*. 2020;36(3):432-40. doi: 10.1016/j.cjca.2020.01.020.
- Tjahjadi C, Fortuni F, Stassen J, Debonnaire P, Lustosa RP, Marsan NA, et al. Prognostic Implications of Right Ventricular Systolic Dysfunction in Cardiac Amyloidosis. *Am J Cardiol*. 2022;173:120-7. doi: 10.1016/j.amjcard.2022.02.048.
- Giblin GT, Cuddy SAM, González-López E, Sewell A, Murphy A, Dorbala S, et al. Effect of Tafamidis on Global Longitudinal Strain and Myocardial Work in Transthyretin Cardiac Amyloidosis. *Eur Heart J Cardiovasc Imaging*. 2022;23(8):1029-39. doi: 10.1093/ehjci/jeac049.
- Usuku H, Takashio S, Yamamoto E, Yamada T, Egashira K, Morioka M, et al. Prognostic Value of Right Ventricular Global Longitudinal Strain in Transthyretin Amyloid Cardiomyopathy. *J Cardiol*. 2022;80(1):56-63. doi: 10.1016/j.jcc.2022.02.010.



21. Shah SJ, Fine N, Garcia-Pavia P, Klein AL, Fernandes F, Weissman NJ, et al. Effect of Tafamidis on Cardiac Function in Patients With Transthyretin Amyloid Cardiomyopathy: A Post Hoc Analysis of the ATTR-ACT Randomized Clinical Trial. *JAMA Cardiol.* 2024;9(1):25-34. doi: 10.1001/jamacardio.2023.4147.
22. Barros-Gomes S, Williams B, Nhola LF, Grogan M, Maalouf JF, Dispenzieri A, et al. Prognosis of Light Chain Amyloidosis With Preserved LVEF: Added Value of 2D Speckle-Tracking Echocardiography to the Current Prognostic Staging System. *JACC Cardiovasc Imaging.* 2017;10(4):398-407. doi: 10.1016/j.jcmg.2016.04.008.
23. Bandera F, Martone R, Chacko L, Ganesanathan S, Gilbertson JA, Ponticos M, et al. Clinical Importance of Left Atrial Infiltration in Cardiac Transthyretin Amyloidosis. *JACC Cardiovasc Imaging.* 2022;15(1):17-29. doi: 10.1016/j.jcmg.2021.06.022.
24. Mohty D, Petitalot V, Magne J, Fadel BM, Boulogne C, Rouabhia D, et al. Left Atrial Function in Patients with Light Chain Amyloidosis: A Transthoracic 3D Speckle Tracking Imaging Study. *J Cardiol.* 2018;71(4):419-27. doi: 10.1016/j.jcc.2017.10.007.
25. Nemes A, Földeák D, Domsik P, Kalapos A, Kormányos Á, Borbényi Z, et al. Right Atrial Deformation Analysis in Cardiac Amyloidosis - Results from the Three-Dimensional Speckle-Tracking Echocardiographic MAGYAR-Path Study. *Arq Bras Cardiol.* 2018;111(3):384-91. doi: 10.5935/abc.20180150.
26. Ladefoged B, Pedersen ALD, Clemmensen TS, Poulsen SH. Strain-derived Myocardial Work in Wild-type Transthyretin Cardiac Amyloidosis with Aortic Stenosis-diagnosis and Prognosis. *Echocardiography.* 2023;40(10):1079-87. doi: 10.1111/echo.15681.
27. Antonelli J, Neveu A, Kosmala W, L'Official G, Curtis E, Oger E, et al. Evolution and Prognostic Value of Left Ventricular Deformation and Myocardial Work Parameters in Transthyretin Amyloid Cardiomyopathy. *Eur Heart J Cardiovasc Imaging.* 2024;25(4):469-79. doi: 10.1093/ehjci/jead318.
28. Khan S, Fakhouri F, Majeed W, Kolipaka A. Cardiovascular Magnetic Resonance Elastography: A Review. *NMR Biomed.* 2018;31(10):e3853. doi: 10.1002/nbm.3853.
29. O'Shea A, Pierce TT. US Elastography in Hepatic Fibrosis-Radiology In Training. *Radiology.* 2021;299(2):264-71. doi: 10.1148/radiol.2021203893.
30. Pislaru C, Ionescu F, Alashry M, Petrescu I, Pellikka PA, Grogan M, et al. Myocardial Stiffness by Intrinsic Cardiac Elastography in Patients with Amyloidosis: Comparison with Chamber Stiffness and Global Longitudinal Strain. *J Am Soc Echocardiogr.* 2019;32(8):958-68. doi: 10.1016/j.echo.2019.04.418.
31. Maurer MS, Elliott P, Merlini G, Shah SJ, Cruz MW, Flynn A, et al. Design and Rationale of the Phase 3 ATTR-ACT Clinical Trial (Tafamidis in Transthyretin Cardiomyopathy Clinical Trial). *Circ Heart Fail.* 2017;10(6):e003815. doi: 10.1161/CIRCHEARTFAILURE.116.003815.
32. Ghoneem A, Bhatti AW, Khadke S, Mitchell J, Liu J, Zhang K, et al. Real-World Efficacy of Tafamidis in Patients With Transthyretin Amyloidosis and Heart Failure. *Curr Probl Cardiol.* 2023;48(6):101667. doi: 10.1016/j.cpcardiol.2023.101667.
33. Maurer MS, Kale P, Fontana M, Berk JL, Grogan M, Gustafsson F, et al. Patisiran Treatment in Patients with Transthyretin Cardiac Amyloidosis. *N Engl J Med.* 2023;389(17):1553-65. doi: 10.1056/NEJMoa2300757.

